

ABDOMINAL WOUND

Abdominal Wound – Fournier Abscess

Female

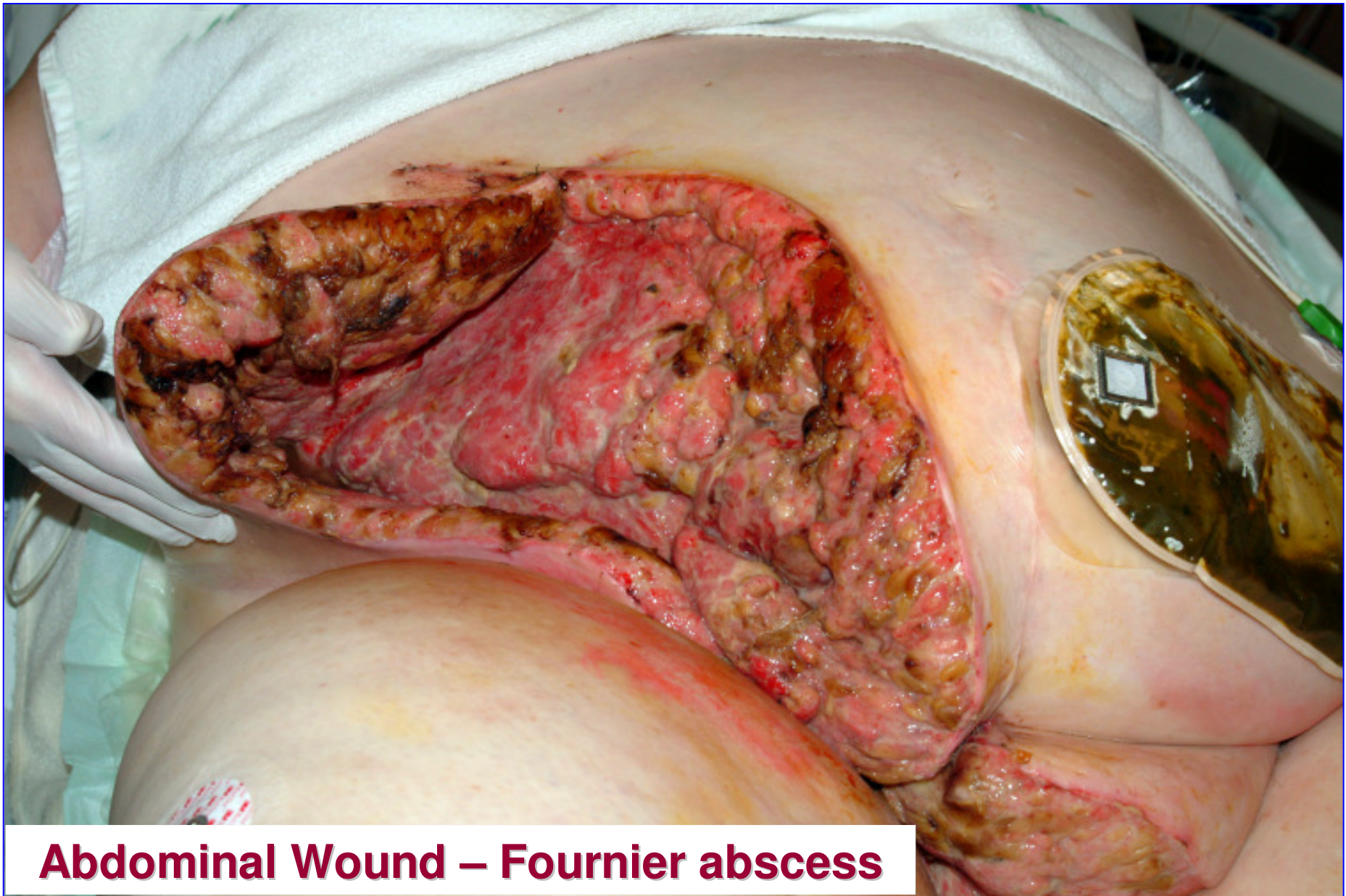
Age: 71 Years

Start Q.Light[®]: 04/09/2006

Full Closure: 13/11/2006

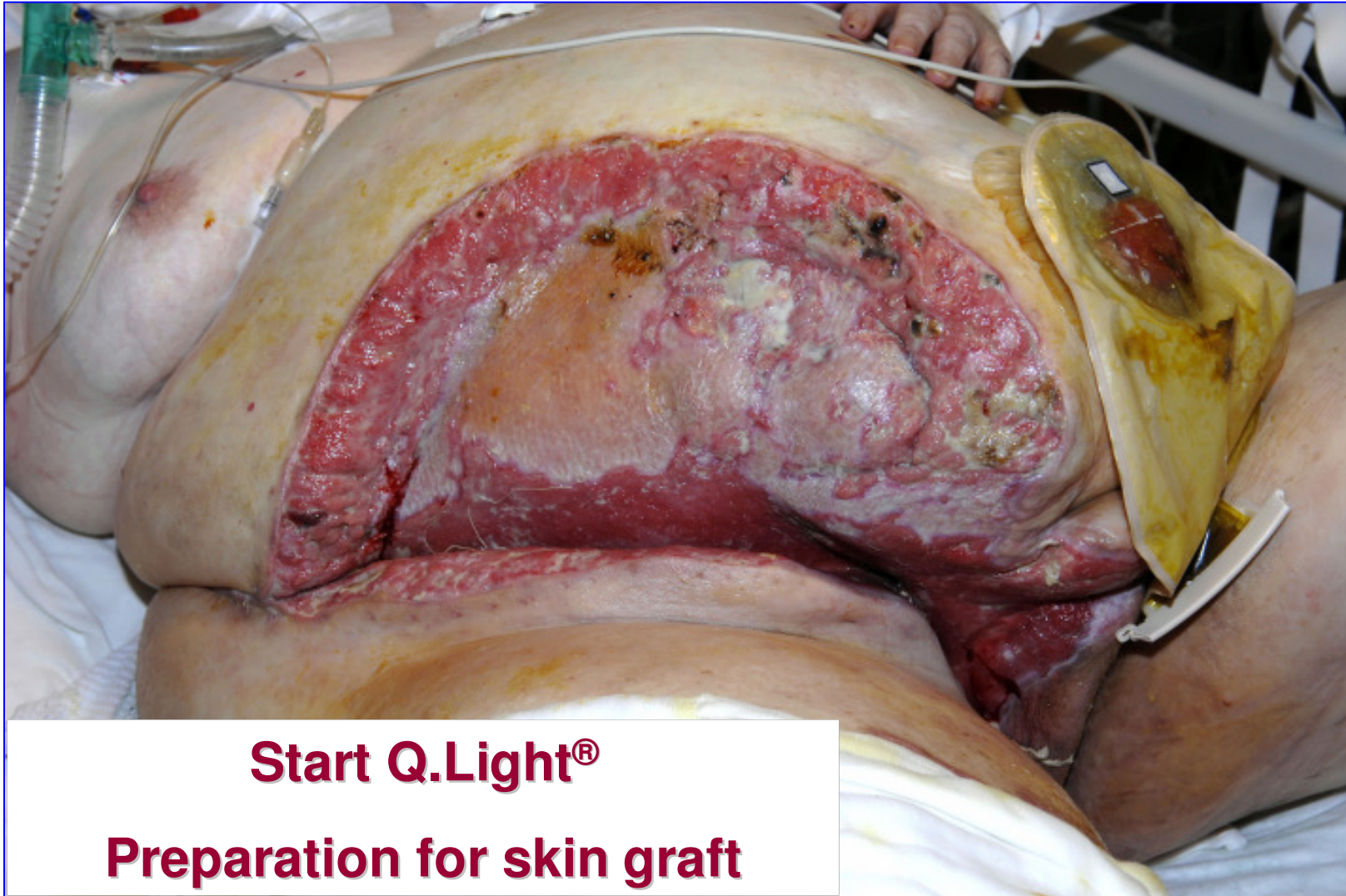Total Treatment Time: 2 months

Treatment: 12 minutes daily



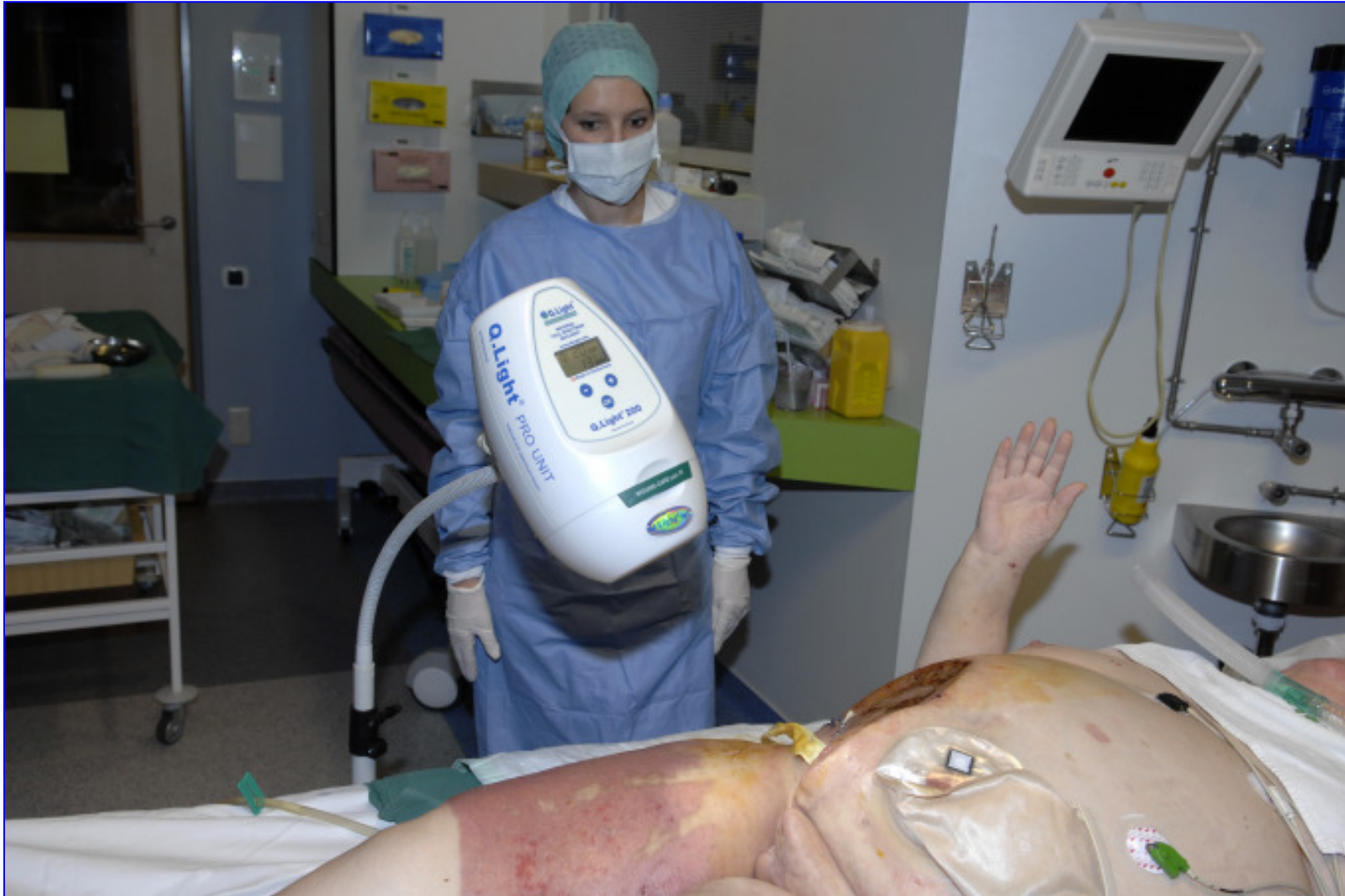Abdominal Wound – Fournier abscess

Skin Defects after Mesh Grafts



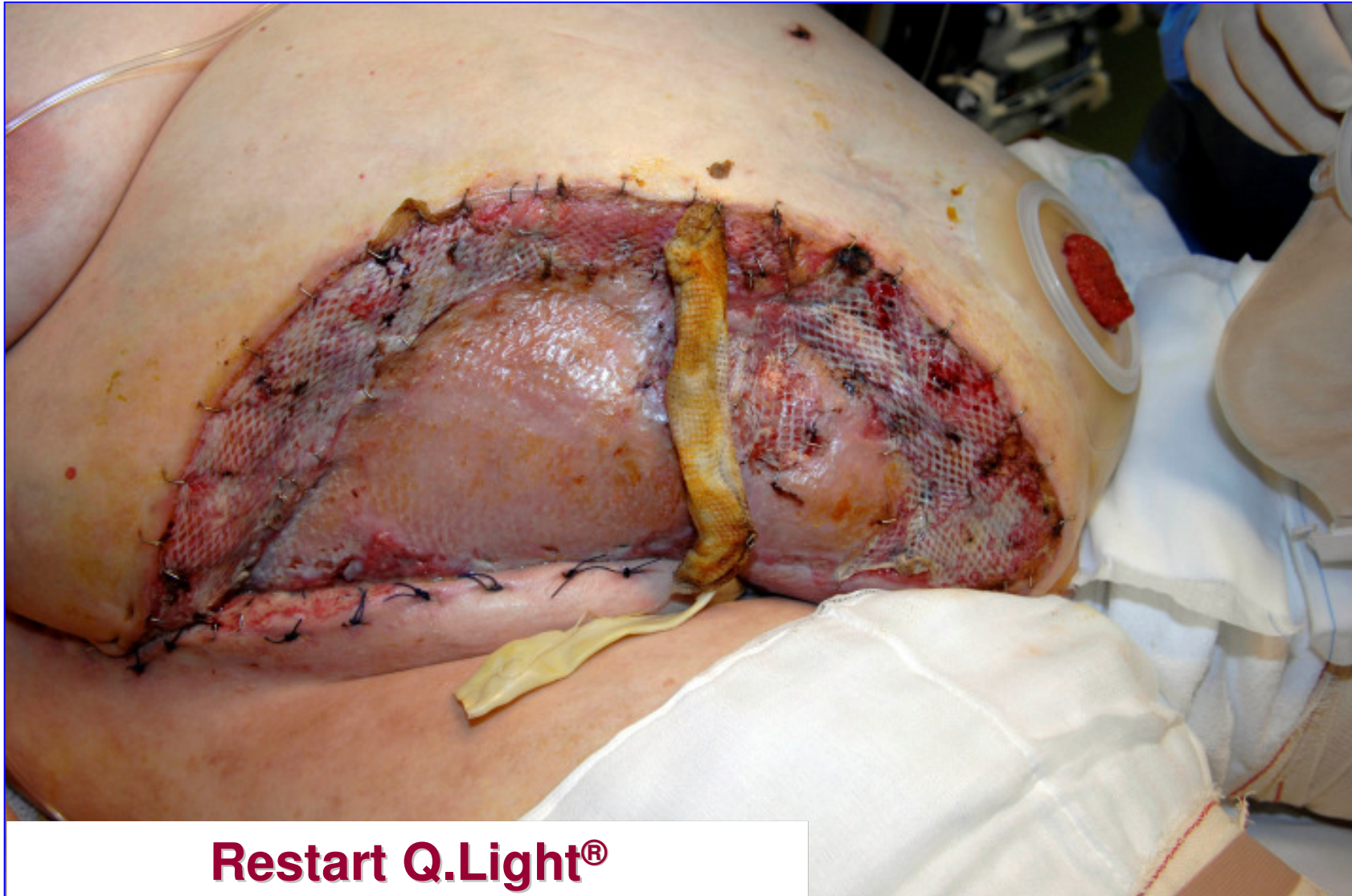
Start Q.Light®
Preparation for skin graft

Q.LIGHT®

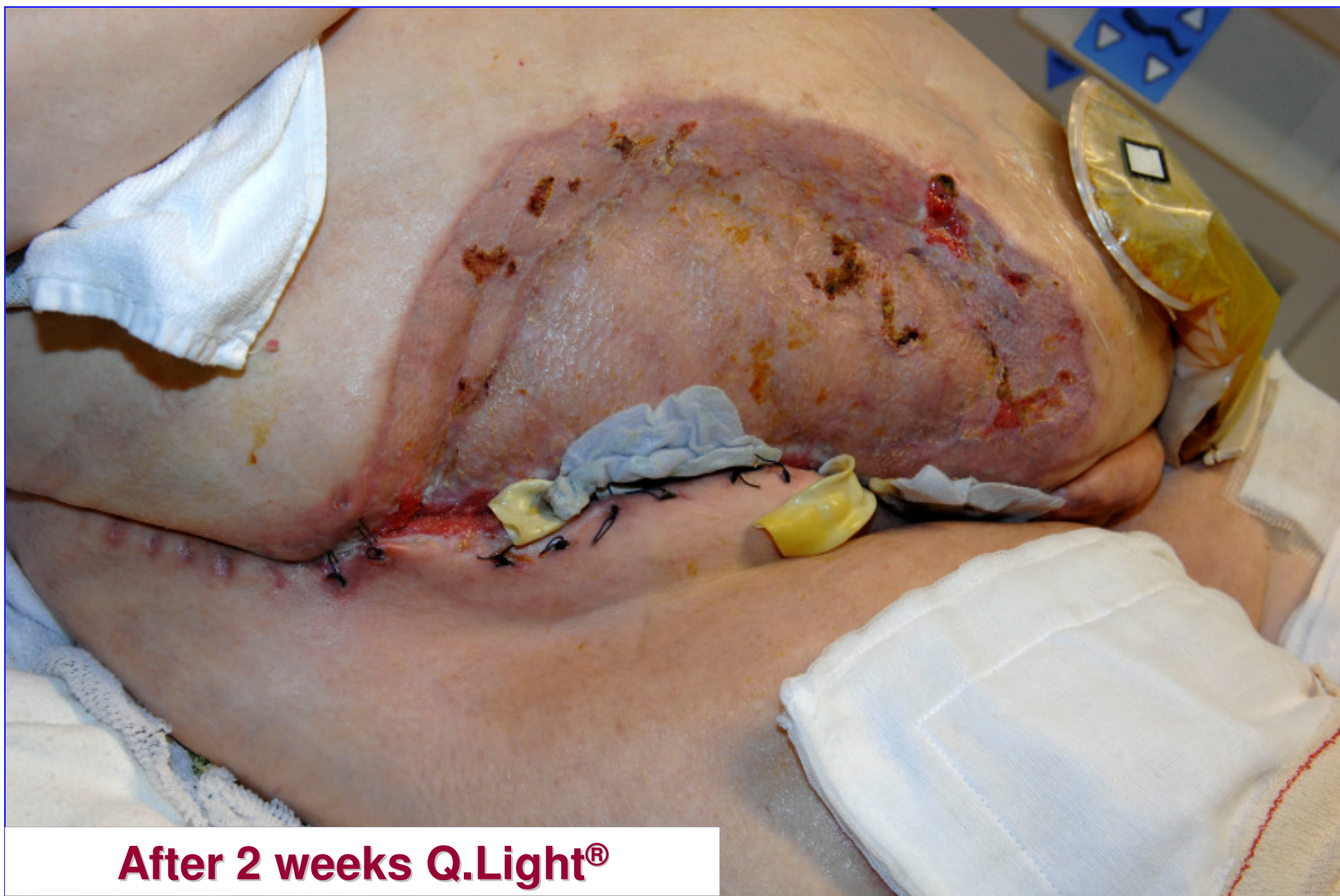

Dept of Plastic & Reconstructive Surgery / University Hospital Gent

Second mesh graft procedure

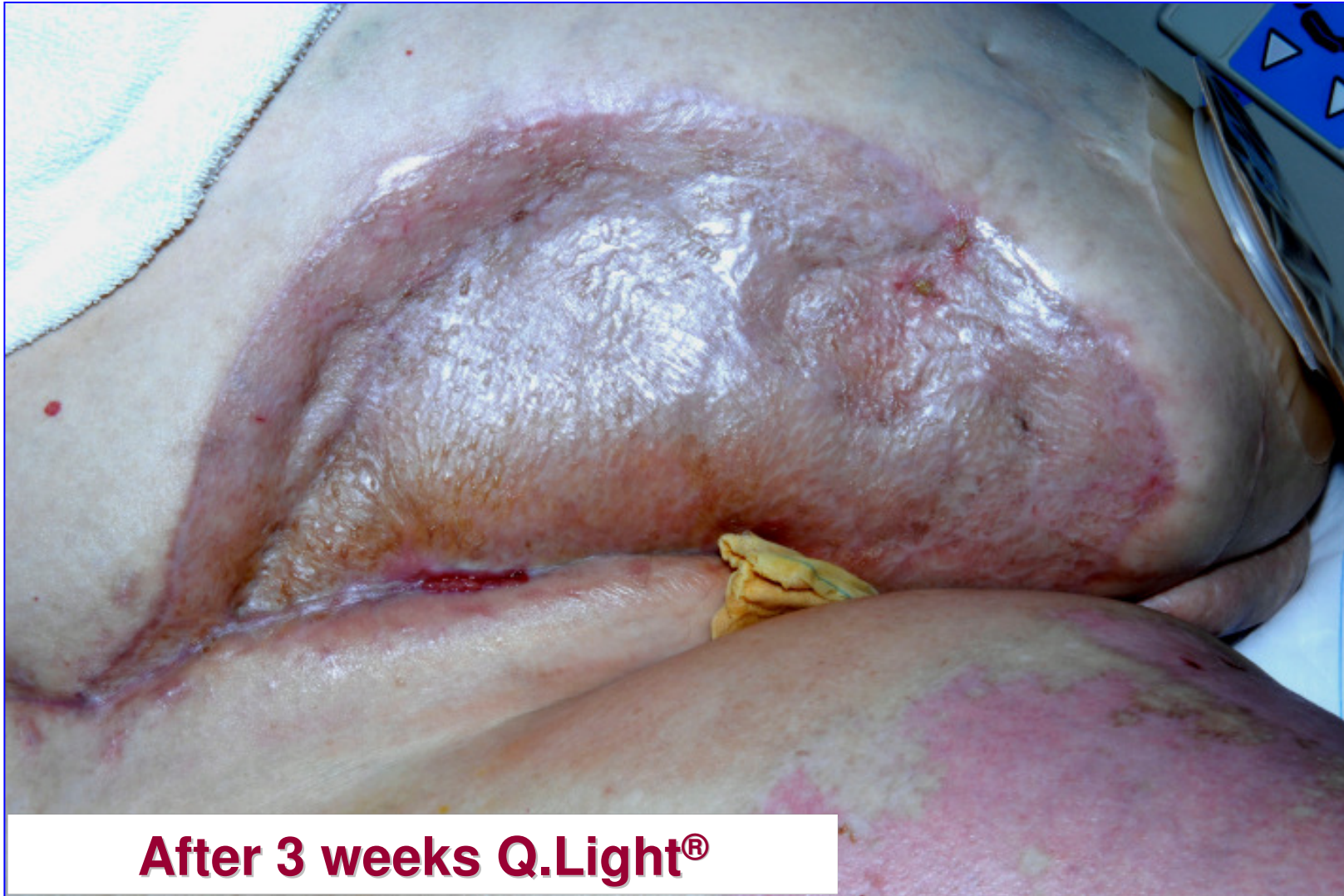

Restart Q.Light®

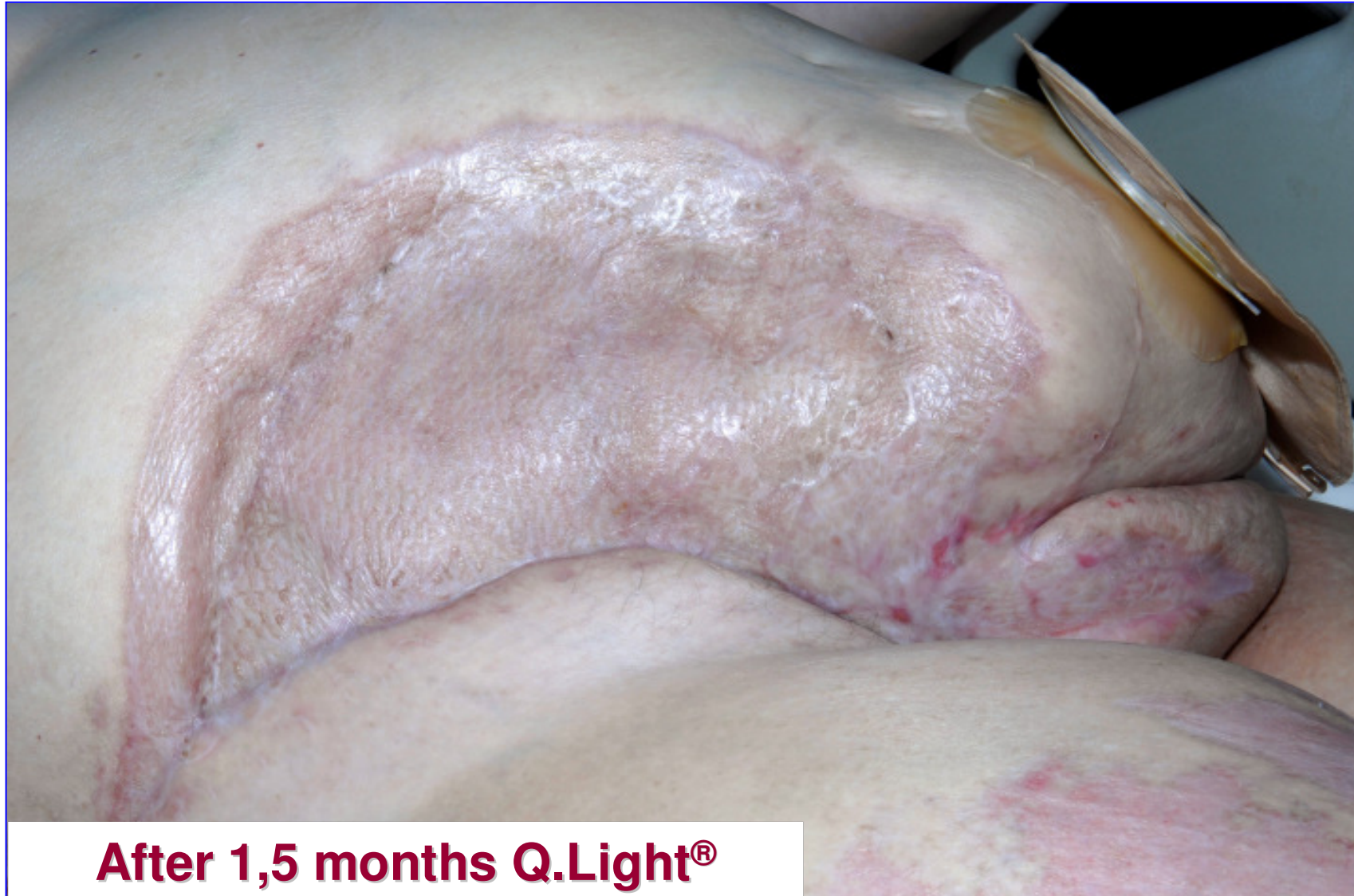

After 2 weeks Q.Light®

Q.LIGHT®



Q.LIGHT®



After 1,5 months Q.Light®